



**PRESENTING CLINICAL SIGNS**

History: Slowing down, urinating on floor, eating less, losing weight, sleeping a lot, hiding. SNAP BNP abnormal. Other BW WNL. Radiographs show a mildly enlarged cardiac silhouette.

DATE

4/5/23

**ECHOCARDIOGRAPHIC FINDINGS**

2D, M-mode, and Doppler study.

PERFORMED BY:

Dr. Brian Barnes

INTERPRETED BY

Keith Blass, DVM,  
MS, DACVIM  
(Cardiology)

Left atrial size is normal. The mitral valve appears normal, though mild mitral regurgitation is present. Left ventricular wall thickness is normal. Left ventricular internal dimensions are normal. Left ventricular systolic function is hyperdynamic. The aorta and aortic valve are normal. Right atrial and right ventricular dimensions are normal. The tricuspid valve appears normal, though trace tricuspid regurgitation is present. There is mild dynamic obstruction to flow in the right ventricular outflow tract. The pulmonary artery and pulmonic valve are normal. No shunting lesions are visualized. No heartworms are visualized. No pericardial effusion or cardiac masses are seen.

ECG during echo: Sinus rhythm

PATIENT

Little Man Shawcross

IVSd - 5.4 mm  
LVPWd - 5.4 mm  
LVIDd - 11.8 mm  
LVIDs - 5.2 mm  
FS - 55.9%  
RA - 19.5 mm  
LVOT - 1.93 m/s  
RVOT - 2.15 m/s

SPECIES

Feline

**ASSESSMENT/RECOMMENDATIONS**

BREED

DMH

SEX

MN

This examination demonstrates mild regurgitation of blood across Little Man's mitral valve. The hemodynamic effects of the regurgitation also appear to be mild, as Little Man does not have secondary dilation of his left atrium, indicating that his current risk for the development of congestive heart failure and/or thromboembolic disease appears to be low.

No therapy is recommended at this stage of disease.

A recheck echocardiogram is recommended in ~6 months to monitor for disease progression.

AGE

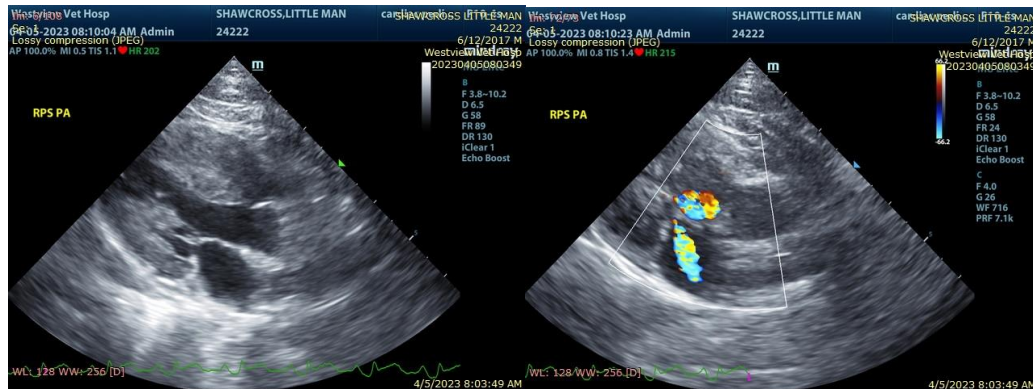
5 y

WEIGHT

7.6 kg

HOSPITAL NAME

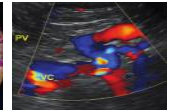
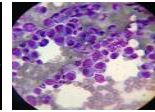
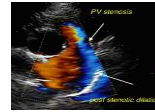
Westview VH



REFERRING VET

Dr. Barnes

The information and recommendations provided are based on the images presented by the



referring veterinarian. No evaluation can be communicated regarding pathology that was not visible in the image/video clips provided.

**DATE**

4/5/23

Thank you for this referral. If the clinical or image interpretation does not parallel your findings or if I can be of any further assistance please contact me.

**PERFORMED BY:**

**Keith Blass, DVM, MS, DACVIM (Cardiology)**

KeithBlass@gmail.com

631-804-5754

Dr. Brian Barnes

**INTERPRETED BY**

Keith Blass, DVM,  
MS, DACVIM  
(Cardiology)

**PATIENT**

Little Man Shawcross

**SPECIES**

Feline

**BREED**

DMH

**SEX**

MN

**AGE**

5 y

**WEIGHT**

7.6 kg

**HOSPITAL NAME**

Westview VH

**REFERRING VET**

Dr. Barnes